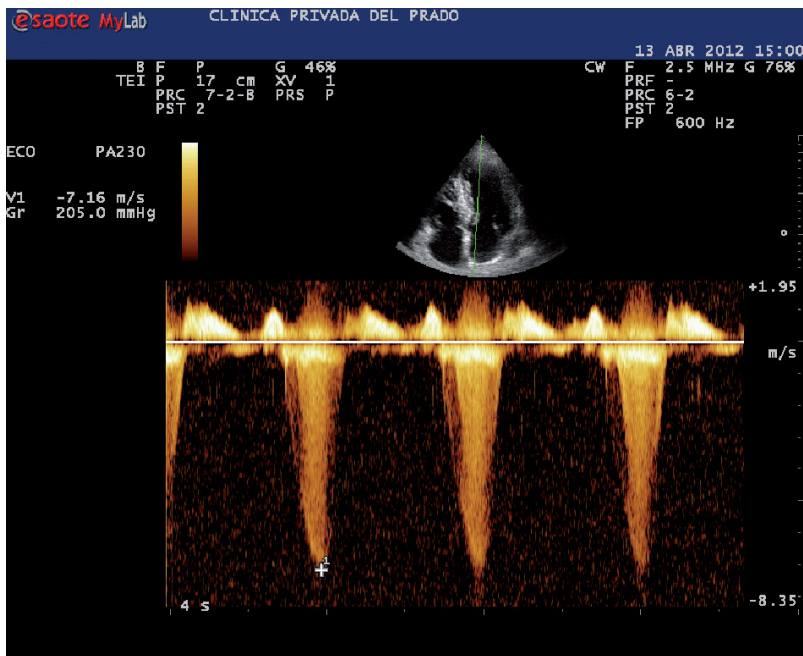


Extreme gradient in hypertrophic cardiomyopathy

DANIEL F. MORISSE¹, RODOLFO GAVÍCOLA¹, DANIEL AVAYÚ²

The image corresponds to a 73 year-old male, hypertensive and important long-term smoker patient, without any other relevant previous medical history. He attended the hospital for a Doppler echocardiography due to 2/6 systolic murmur over the aortic focus detected in the physical exam, and presumptive

diagnosis of aortic valve stenosis. The patient was asymptomatic. The study revealed hypertrophic cardiomyopathy causing partial obstruction of the left ventricular outflow tract, with peak systolic velocity recordings of 7 meters per second and intraventricular gradient over 200 mm Hg.



¹ MD, Echocardiographer Clínica Privada del Prado, Córdoba
² Head of Echocardiography at Hospital "Teodoro Álvarez", Buenos Aires
 e-mail: danielmorisse@yahoo.com.ar