

Neovessels as Source of Intraplaque Hemorrhage

JOSÉ MILEI^{MTSAC, 1}

In this issue of the Journal, Duronto et al. (1) publish their study about the presence of angiogenesis (ANG) in vulnerable atherosclerotic plaques in apparently healthy transplant donors older than 40 years. The study was directed by Dr. R Laguens and Dr. E. Gurfinkel, who prematurely passed away in 2011.

In a detailed study, they correlated ANG in atherosclerotic plaques with the criteria used by the American Heart Association. The coronary arteries and all stenotic areas underwent histological, immunohistochemical and morphometric studies. Angiogenesis in vulnerable plaques was associated with vascular occlusion, inflammatory cell infiltration, fibrosis, lipid core, and hypertension (HT) in lesions of the left anterior descending coronary artery. The presence of angiogenesis was detected in 50/143 advanced lesions (type IV, V and VI lesions) (34.9%) compared with 6/220 low-risk plaques (2.7%) ($p < 0.001$), suggesting that ANG may anticipate plaque rupture. **However, no association with calcification or intraplaque hemorrhage (IH) was found.**

It is worthwhile to analyze the pathophysiology of IH due to its importance in plaque instability and disruption.

NEOVESSELS

Neovessels and vasa vasorum increase as the plaque develops. The vasa vasorum form a microvasculature network that originates primarily in the main artery and branch plexogenically in the adventitia to supply blood to the arterial wall. (2) As the atherosclerotic plaque develops, neovessels originating from the vasa vasorum that course through the medial layer are responsible for 70% of intraplaque vessels. The remaining 30% neovessels are derived from the lumen. (3) The increase in neocapillaries and their arborization from the vasa vasorum, documented by injecting contrast agents in the parent artery, is proportional to the extent of the atherosclerotic disease. (4)

NEOVESSELS AS SOURCE OF INTRAPLAQUE HEMORRHAGE

Pathologists have observed for decades the coexistence of neocapillaries and IH. In addition, the presence of hemosiderin as an indicator of previous hemorrhage has been associated with neovascularization, and is higher in patients with acute coronary syndromes

than in those with non-cardiac causes of death. (5) An increase in the amount of lipid in the core, mechanical stress (6, 7) and an overproduction of oxygen free radicals by macrophages could lead to the breakdown of core neovessels and IH. (8) The expression of the anti-oxidant protein thioredoxin, which has been found to be up-regulated in “culprit” coronary arteries in response to increased oxidative stress and associated to IH, could be a marker of plaque instability. (9)

The association between neovascularization and IH is logical; neocapillaries consist of a single incomplete lining of endothelial cells on a basement membrane, devoid of smooth muscle cells, which turns them more susceptible to rupture. (10) The predisposition to rupture is further increased by their critical proximity to the lipid core. This core is a weak structure lacking intercellular matrix, and its interface with the fibrous cap or the collagenous base of the plaque in contact with the medial layer bears the circumferential wall stress and the hemodynamic mechanical shear stress induced by systolic and diastolic pressure fluctuations. (10) In addition to greater expression of proteinases by macrophages in the vicinity of the neocapillaries, (8, 11, 12) the mechanical stress produced by turbulent flow and wall vibrations secondary to arterial wall stiffness might contribute to neovessel rupture. (6)

The presence of old hemorrhages in 48% complicated plaques and slit-like hemorrhages distal to the main hemorrhage is strongly suggestive of local bleeding (11) associated with the described stress. (6) Moreover, we have demonstrated that lipid cores are highly vascularized by heterogeneous vessels in contact with macrophage and T-lymphocyte infiltrate (in some cases, migrating through the endothelial cells), with local production of proteinases (12) and oxygen free radicals that could lead to the breakdown of core vessels and IH. (8, 12)

Our observations and those of other authors suggest that **hemorrhage may occur at any moment in the development of atherosclerosis and even in multiple occasions may be asymptomatic and distal to the main lesion** (Figures 1 and 2). (2, 7, 11, 13)

EFFECTS OF INTRAPLAQUE HEMORRHAGE ON THE LIPID CORE

Neoangiogenesis is strongly associated with plaque progression. In the development of lipid cores, the

^{MTSAC} Full Member of the Argentine Society of Cardiology

¹ Director, Instituto de Investigaciones Cardiológicas “Prof. Dr. Alberto C. Taquini” - UBA - CONICET (ININCA)

majority of adventitial vessels invade them at specific sites of medial wall disruption. A breach in the medial wall likely facilitates the rapid in-growth of microvessels from the adventitia, and exposure to atherosclerotic tissue stimulates abnormal vascular development, characterized by disorganized branching and immature endothelial tubes with leaky linings.

This network is a source of IH providing erythrocyte-derived phospholipids and free cholesterol. The rapid change in plaque substrate caused by the excessive accumulation of erythrocytes may promote the transition from a stable to an unstable lesion. (14) Since IH occupies part of the plaque area, it contributes to greater deposition of lipids in the plaque, increasing the core size and lumen narrowing. (15)

Various lipids are potent endothelial mitogens predisposing to ANG and IH. In addition, cytokines and vascular cell adhesion factors are essential for the growth of these vessels (17)

Studies evaluating the necrotic core progression have identified IH as a critical factor for plaque growth and instability.

DIFFERENCES BETWEEN CORONARY ARTERIES AND CAROTID ARTERIES

Some years ago, we postulated that IH is more common in the carotid arteries and that luminal thrombi

occur more frequently in coronary artery plaques due to differences in the type and size of these arteries (elastic vs. muscular artery), hemodynamic forces and vasoreactivity (8)

However, in an editorial article, Virmani et al. (10) remarked that although the carotid artery is an elastic artery, and the coronary artery is a muscular artery: a) the overall atherosclerotic process is not different in the two vascular locations, b) the cells and the noncellular components participating in the atherogenic process are similar, c) the lesions occur most commonly at branching points in both arteries, d) the types of complications in the atherosclerotic plaque are also similar, and, e) the greater blood flow and size of the carotid artery can partially explain the delay in the development of symptomatic carotid disease compared with the coronary atherosclerotic process.

Regarding frequency, thrombosis was found in 60% sudden coronary deaths, whereas it significantly increased to 90% in acute myocardial infarction. Conversely, in carotid endarterectomy specimens, rupture of the fibrous cap was seen in 74% symptomatic and 32% asymptomatic patients. (18) Intraplaque hemorrhage was observed in all specimens from the symptomatic group and in 68% specimens from asymptomatic patients. A similar incidence of IH and rupture

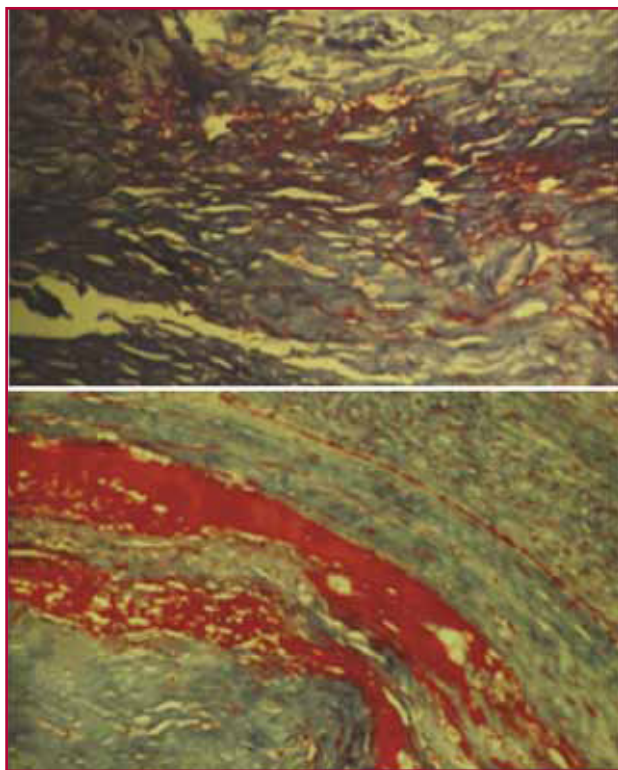


Fig. 1. A. Recent interstitial and confluent hemorrhage (trichrome stain x 100). **B.** Extensive laminated hemorrhage (trichrome stain x 100). **C.** Plaque hemorrhage with high lipid content and thick cap (trichrome stain x 40).

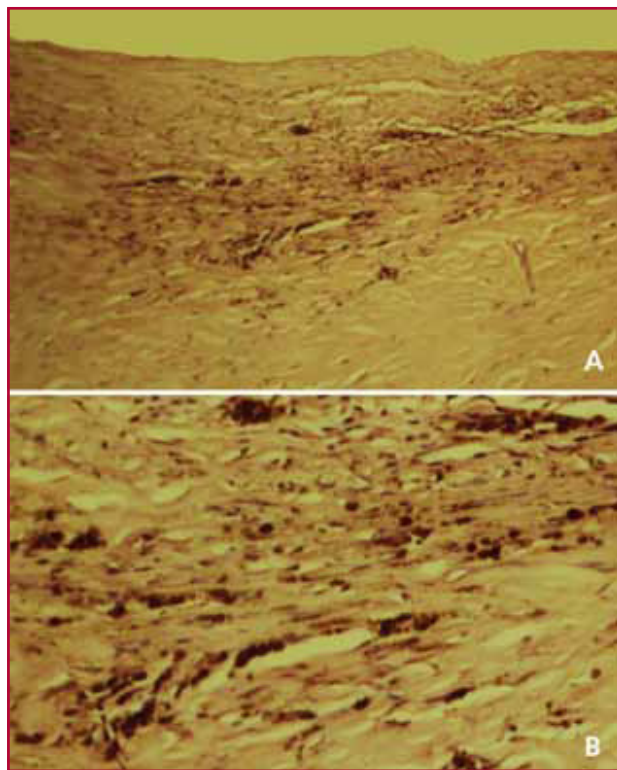


Fig. 1. A. Panoramic view. Extensive hemosiderin depot, indicative of previous hemorrhage, on the base of a fibrous plaque (HE x 40). **B.** Detail of hemosiderin depot shown in **A.** (HE x 100).

has also been reported in other publications. (19)

OUR EXPERIENCE

Almost a decade ago, we published histological and histochemical findings in 165 carotid endarterectomy specimens to evaluate the pathogenesis of plaque rupture and IH. (8) Seventy percent specimens presented a thrombus, hemorrhage, or both in the plaque. Thrombosis was seen in one third, whereas IH was observed in two thirds of the cases. Almost all these specimens showed plaque neovascularization. The neocapillaries were located at the base and shoulder of the plaque surrounding the lipid core or within the core itself with adjacent inflammation. As pointed out by Virmani et al. in their editorial article, **the universal presence of intraplaque neovascularization indicates its important role in the origin of IH.** (10) In the abstract of our study, (8) we emphasized that: "... HI without rupture had highly vascularized lipid cores in all cases. An infiltrate consisting of T-lymphocytes and macrophages was observed in close contact with the neoformed vessels." (2) These findings were confirmed in a later study with 281 endarterectomy specimens. (19)

Finally, we consider that ANG is the cause and consequence of plaque progression to more vulnerable lesions capable of inducing plaque rupture and its ensuing outcome. Thus, understanding the mechanisms that produce it may lead to the development of new therapies focused on plaque stabilization.

In that sense, IH may represent an indication of accelerated plaque growth and impending luminal involvement of a subclinical artery, as shown by magnetic resonance imaging. (20). Statin therapy may stabilize lesions by slowing or halting lesion progression. This phase of carotid plaque stenosis (16% to 49%) may be a critical stage for intrinsic and extrinsic factors to affect the progress of atherosclerotic disease. (21)

REFERENCES

- Duronto EA, Vigliano C, Cabeza Meckert P, Bertolotti A, Laguens R, Gurfinkel E. Presencia de angiogénesis en placas vulnerables ateroscleróticas en corazones humanos aparentemente sanos. *Rev Argent Cardiol* 2012;80:XXX-XXX.
- Persson AV, Robichaux WT, Silverman M. The natural history of carotid plaque development. *Arch Surg* 1983;118:1048-52.
- Fryer JA, Myers PC, Appleberg M. Carotid intraplaque hemorrhage: the significance of neovascularity. *J Vasc Surg* 1987;6:341-9.
- Kumamoto MY, Nakashima Y, Sueishi K. Intimal neovascularization in human coronary atherosclerosis: its origin and pathophysiological significance. *Hum Pathol* 1995;26:450-6.
- Barger AC, Beeuwkes R, Lainey LL, Silverman KJ. Vasa vasorum and neovascularization of human coronary arteries. *N Engl J Med* 1984;310:175-7.
- Lusby RJ, Ferrel LD, Ehrenfeld WK, Stoney J, Wylie EJ. Carotid plaque hemorrhage: its role in the production of cerebral ischemia. *Arch Surg* 1982;117:1479-88.
- Van Damme H, Vivario M, Boniver J, Limet R. Histologic characterization of carotid plaques. *Cardiovasc Pathol* 1994;3:9-17.
- Milei J, Parodi JC, Alonso GF, Barone A, Grana D, Maturri L. Carotid rupture and intraplaque hemorrhage: immunophenotype and role of cells involved. *Am Heart J* 1998;136:1096-105.
- Nishihira K, Yamashita A, Imamura T, Hatakeyama K, Sato Y, Nakamura H, et al. Thioredoxin in coronary culprit lesions: possible relationship to oxidative stress and intraplaque hemorrhage. *Atherosclerosis* 2008;201:360-7.
- Virmani R, Narula J, Farb A. When neoangiogenesis ricochets. *Am Heart J* 1998;136:937-9.
- Milei J, Parodi JC, Fernández Alonso G, Barone A, Beigelman R, Ferreira LM, et al. Carotid atherosclerosis: immunocytochemical analysis of the vascular and cellular composition in endarterectomies. *Cardiologia* 1996;41:535-42.
- Nikkari ST, O'Brien KD, Ferguson M, Hatsukami T, Welgus HG, Alpers CE, et al. Interstitial collagenase (MMP-1) expression in human carotid atherosclerosis. *Circulation* 1995;92:1393-8.
- Clinical Advisory. Carotid endarterectomy for patients with asymptomatic internal carotid artery stenosis. *Stroke* 1994;25:2523-4.
- Virmani R, Kolodgie FD, Burke AP, Finn AV, Gold HK, Tulenko TN, et al. Atherosclerotic plaque progression and vulnerability to rupture: angiogenesis as a source of intraplaque hemorrhage. *Arterioscler Thromb Vasc Biol* 2005;25:2054-61.
- Imparato AM, Riles TS, Mintzer R, Baumann FG. The importance of hemorrhage in the relationship between gross morphologic characteristics and cerebral symptoms in 376 carotid artery plaques. *Ann Surg* 1982;197:195-203.
- Rice GC. Endogenous angiogenic lipids. En: IBC's 2nd Conference on Therapeutic Implications and Mechanisms of Angiogenesis Inhibitors and Stimulators. May 8-10, 1996. San Francisco, Calif.
- Friedlander M, Brooks P, Shaffer RW, Kinkaid CM, Vamer JA, Cheresch DA. Definition of two angiogenic pathways by distinct alpha v integrins. *Science* 1995;270:1500-2.
- Virmani R, Roberts WC. Extravasated erythrocytes, iron and fibrin in atherosclerotic plaques of coronary arteries in fatal coronary heart disease and their relation to luminal thrombus: frequency and significance in 57 necropsy patients in 2958 segments of 224 major epicardial coronary arteries. *Am Heart J* 1983;105:788-97.
- Milei J, Parodi JC, Ferreira M, Barone A, Grana DR, Maturri L. Atherosclerotic plaque rupture and intraplaque hemorrhage do not correlate with symptoms in carotid artery stenosis. *J Vasc Surg* 2003;38:1241-7.
- Daemen MJ, Kooi ME. Intraplaque hemorrhage as a stimulator of episodic growth of advanced, but non symptomatic atherosclerotic lesions bridging the gap. *JACC Cardiovasc Imaging* 2009;1:390-2.
- Underhill HR, Yuan C, Yarnykh VL, Chu B, Oikawa M, Polissar NL, et al. Arterial remodeling in [corrected] subclinical carotid artery disease. *JACC Cardiovasc Imaging* 2009;1:381-9.